



# Iatrogenic Ulnar Nerve Palsy Post Supracondylar K-Wire Insertion: Case Report and Review of Literature

Milly Huang<sup>1\*</sup>, Ash Chehata<sup>2</sup> and Luke J Bonato<sup>1</sup>

<sup>1</sup>Monash University, Clayton, Australia

<sup>2</sup>The Avenue Hospital, Victoria, Australia

## Keywords

Ulnar nerve, Supracondylar, Fracture, Palsy, Iatrogenic

## Introduction

Ulnar nerve damage is a recognised complication of Kirschner wires (K-wire) pinning of supracondylar fractures, and can occur as an iatrogenic consequence of surgery in up to 20% of patients [1-7]. It is thought that most commonly, the process of traction and fracture reduction combined with the overlying swelling results in a transient neuropraxia that will resolve with time. However, iatrogenic ulnar nerve palsy can also result from direct ulnar nerve damage from K-wire insertion; compression from the K-wire causing a cubital tunnel syndrome; or from the ulnar nerve being caught in the fracture site which is more common in flexion type supracondylar fractures [8]. We present 2 cases of iatrogenic ulnar nerve damage following closed reduction and K-wire insertion as a consequence of the K-wire directly penetrating the ulnar nerve.

## Case Presentation

Both cases were second opinions sought out by the parents after neurological changes were found post insertion of K-wires and wanted a single surgeon for continuity of care.

The first case was a 7-year-old otherwise healthy boy fell on an outstretched hand and presented to the Emergency Department with a deformity of his left arm. An X-ray confirmed a closed Gartland type III supracondylar fracture with no neurologic deficit [6]. The fracture was managed with closed reduction and cross K-wires and immediately post-operatively the patient developed progressive paresthesia, change in sensation in the

distribution of the ulnar nerve, and a new ulnar claw deformity of his hand. A small open incision anterior to the wire was present, performed by the surgeon (at the time of the original closed reduction and K-wire insertion) in keeping with an exploration of the nerve which was felt to be intact and not involving the K-wire. The neurologic deficit did not improve over the following week and the patient's family sought another opinion regarding the cause of the persistent numbness and deformity at the 3 week mark.

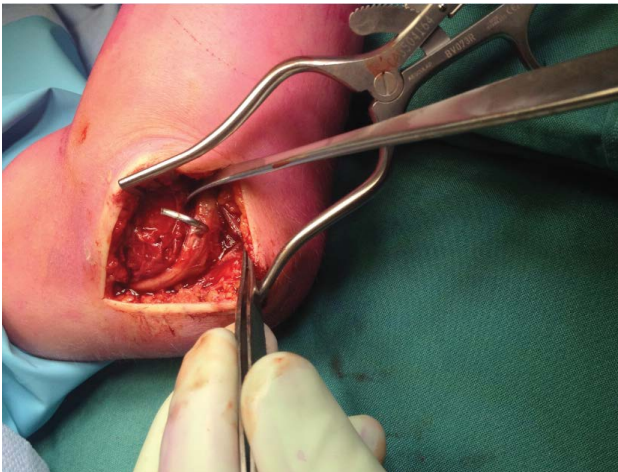
X-rays revealed callous present in a slightly malrotated distal fragment, at 3 weeks post-injury. A decision was made to remove the K-wires and to explore the nerve to ensure the nerve was in continuity and not trapped in the fracture site.

The patient subsequently underwent exploration of the ulnar nerve which demonstrated that the medial K-wire had directly pierced through the nerve (Figure 1). The ulnar nerve was otherwise in continuity, not trapped in the fracture site and preserved. The medial wire was removed from the ulnar nerve and the fracture was confirmed to be stable and uniting by fluoroscopy. The fracture was managed

**\*Corresponding author:** Milly Huang, MBBS, Monash University, Suite 31, Cabrini Hospital, Malvern Isabella Street, Malvern, Victoria 3144, Australia, E-mail: [milly.sj.huang@gmail.com](mailto:milly.sj.huang@gmail.com)

**Received:** October 02, 2017; **Accepted:** October 28, 2017;  
**Published online:** October 30, 2017

**Citation:** Huang M, Chehata A, Bonato LJ (2017) Iatrogenic Ulnar Nerve Palsy Post Supracondylar K-Wire Insertion: Case Report and Review of Literature. J Orthop Rheumatism 1(2):24-27



**Figure 1:** K-wire piercing directly through the ulnar nerve.

subsequently with back-slab immobilisation.

Two weeks post-procedure, the patient showed clinical and radiological union with a large amount of subperiosteal new bone formation seen on the lateral aspect of the distal humerus.

Four weeks post-exploration, the patient reported no remaining neurovascular complications in his hands, including no anaesthesia or paresthesia. He had a slight loss of 20 degrees of flexion and extension. This continued to improve with a four month follow-up examination showing that extension had fully improved, with flexion reduced at 110 degrees likely due to the malrotation and the parents and the patient were happy with the outcome.

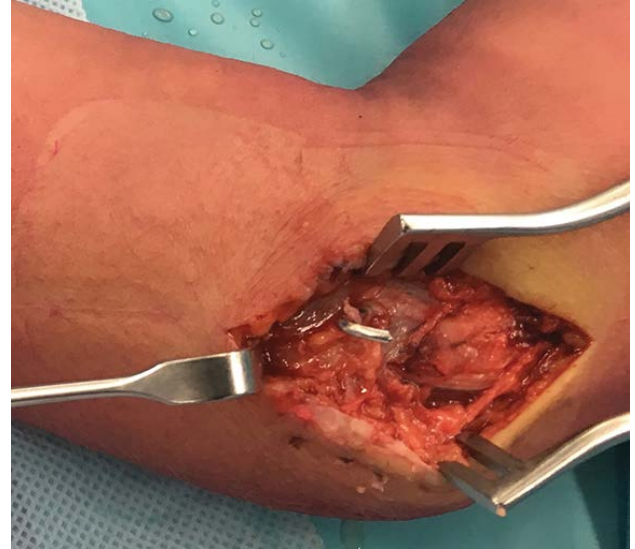The second patient was a 9-year-old otherwise healthy girl who fell and developed a Gartland III supracondylar fracture of the right humerus with vascular compromise (no pulse). She was operated on immediately, and whilst vascular function returned, the patient developed tingling in her fingers in the ulnar distribution and an ulnar claw. This persisted past three weeks post-op so a decision was made to explore the nerve during K-wire removal at four weeks.

The exploration of the ulnar nerve demonstrated that the medial K-wire had picked up a fibril of the ulnar nerve (Figure 2), which had wrapped around the wire. The ulnar nerve was otherwise in continuity, not trapped in the fracture site and preserved. The wire and nerve were separated.

In her follow-up post-exploration, the second patient's neurologic deficit was found to have fully resolved, with full range of motion recovered at the 8 week mark.

## Discussion

Supracondylar fractures of the humerus are a common injury among paediatric patients. Treatment ranges from



**Figure 2:** K-wire with a fibril of the ulnar nerve wrapped around it.

skeletal traction in hospital when severely swollen to open reduction and internal fixation and antegrade nailing from the proximal humerus. The position of the elbow is also important due to a high number of subluxing ulnar nerves at greater than 90 degrees, therefore pinning should occur at less than 90 degrees of flexion [9]. The treatment of choice for Gartland Type III supracondylar fractures is closed reduction and percutaneous pinning [9,10], however, there is a significant complication risk in the literature [1-15]. A well known and common risk of supracondylar fracture fixation is nerve injury. A review of the literature reports iatrogenic ulnar nerve injury at a rate ranging from 2%-20% [1-7]. Notably, Gartland Type III fractures are associated with a greater number of post-operative nerve palsies compared to Type II [13], as they are associated with greater swelling and damage to the surrounding soft tissues. The normal bony landmarks are not palpable thereby placing the ulnar nerve at risk for iatrogenic injury [3,6,11].

Ulnar nerve injury can be related to the K-wire causing external compression of the cubital tunnel affecting the ulnar nerve as well as indirect nerve contusion from soft tissue swelling [3,14,15]. Direct penetration can occur from single wire insertion or multiple attempts at inserting the K-wire affecting the sheath of the nerve [2,11,16]. The ulnar nerve has also been caught in the fracture site post-reduction although more common in flexion types and requires operative exploration [8].

All other management following iatrogenic ulnar nerve injury is divided. Some authors recommend early removal and surgical exploration [11,13,16], whilst others opt for a more conservative approach removing the wires once union has occurred, based on the likely complete recovery of the ulnar nerve regardless of cause [3,6]. There is a

consensus that resolution of the injury generally occurs in almost all cases within 6 months [2,6]. There are, however, cases without full recovery. One paediatric case in the literature [16] discussed ulnar nerve penetration by a wire in the midsubstance, where the child did not recover. Two other cases of partial recovery of ulnar nerve function are also discussed in the same paper, one involving ulnar nerve penetration at the posterior edge, and the other involving cubital tunnel retinaculum constriction around the ulnar nerve by the wire.

All three cases involve acute neurologic deficit as a direct result of the wire placement. The lack of complete recovery is consistent with Mohler and Hanel's [5] findings that although the ulnar nerve has a moderate regenerative potential, the level of injury significantly affects the outcome. Other studies have suggested that in addition to the level of injury, a delay in surgical exploration results in a longer period of return to normal function [11,14].

Both cases discussed were due to direct penetration of the ulnar nerve by the K-wire, with the second showing part of the ulnar nerve wrapped around the wire. This would be consistent with the high spinning nature of the insertion of the K-wire. This confirms damage to the nerve as a direct result of the wire and removal will allow earlier regeneration rather than keeping the wire *in situ* till union.

Within 1-2 weeks swelling as a cause of injury can be excluded and exploration of the ulnar nerve and removal or reinsertion can occur safely.

In the setting of post wire insertion nerve injury, there is no specific imaging modality that can clearly be used to identify if there has been iatrogenic damage to a nerve. Ultrasound may be used try and assess if the nerve is in continuity [17]. In the setting of nerve damage, the application of ultrasound is variable as the nerve may still appear to be in continuity, although be damaged or tethered, which ultrasound may not be able to accurately identify. Nerve conduction studies may be performed to confirm the presence of a nerve injury. However, nerve conduction studies will not provide information as to the cause of the nerve malfunction, i.e., iatrogenic, due to the trauma or if there is nerve entrapment within the fracture site.

To avoid this complication would mean to avoid a medial wire altogether and use multiple lateral wires [14]. The use of a medial wire is often required in these highly unstable Gartland 3 supracondylar fractures [14].

To prevent this complication, we advocate for the use of a mini open approach to the ulnar nerve. Clear visualisation of the nerve ensures no risk from K-wire insertion or pressure effect on the surrounding skin. The two cases highlight the complexity when severe swelling and displaced fracture

patterns prevent the palpation of clear bony landmarks such as the medial epicondyle. Adequate exposure and visualisation would help prevent this complication from occurring. Early exploration and removal of the K-wire from the nerve can confirm the continuity of the nerve which can influence prognosis and regeneration.

The importance of comprehensive and appropriate informed consent prior to operative intervention is highlighted by the real complication of nerve injury associated with the management of supracondylar fractures. In the setting of a nerve injury, this complication must be rapidly identified and on-going management of the complication carried out expediently. While medico legal literature does not describe specific cases of litigation involving iatrogenic neurological deficit due to a K-wire, it also takes the stance of early repair to reduce the possibility of litigation [18].

## Conclusion

In the setting of new onset post-operative neurologic deficit in Gartland type III supracondylar fractures of the distal humerus it is a real possibility that the ulnar nerve symptoms are related to the K-wire fixation. The published literature supports that the ulnar nerve injury is likely to recover over time although this is not always the case. We prefer immediate removal of the K-wire and exploration at the time of removal with refixation if necessary. This confirms continuity of the nerve, an explanation of symptoms and can provide reassurance to the family. Surgeons must have a clear understanding of the surrounding anatomy and mandatory visualisation of the ulnar nerve is imperative to avoid this complication when treating paediatric supracondylar fractures.

## References

1. Babal JC, Mehlman CT, Klein G (2010) Nerve injuries associated with pediatric supracondylar humeral fractures: A meta-analysis. *J Pediatr Orthop* 30: 253-263.
2. Brown IC, Zinar DM (1995) Traumatic and iatrogenic neurological complications after supracondylar humerus fractures in children. *J Pediatr Orthop* 15: 440-443.
3. Eberl R, Eder C, Smolle E, et al. (2011) Iatrogenic ulnar nerve injury after pin fixation and after antegrade nailing of supracondylar humeral fractures in children. *Acta Orthop* 82: 606-609.
4. Lyons JP, Ashley E, Hoffer MM (1998) Ulnar nerve palsies after percutaneous cross-pinning of supracondylar fractures in children's elbows. *J Pediatr Orthop* 18: 43-45.
5. Mohler LR, Hanel DP (2006) Closed fractures complicated by peripheral nerve injury. *J Am Acad Orthop Surg* 14: 32-37.
6. Otsuka NY, Kasser JR (1997) Supracondylar fractures of the humerus in children. *J Am Acad Orthop Surg* 5: 19-26.
7. Slobogean BL, Jackman H, Tennant S, et al. (2010) Iatrogenic ulnar nerve injury after the surgical treatment of displaced supracondylar fractures of the humerus: Number needed to

- harm, a systematic review. *J Pediatr Orthop* 30: 430-436.
8. Wingfield JJ, Ho CH, Abzug JM, et al. (2015) Open reduction techniques for supracondylar humerus fractures in children. *J Am Acad Orthop Surg* 23: e72-e80.
  9. Mazzini JP, Martin JR, Estaban EMA (2010) Surgical approaches for open reduction and pinning in severely displaced supracondylar humerus fractures in children: A systematic review. *J Child Orthop* 4: 143-152.
  10. Lee S, Park MS, Chung CY, et al. (2012) Consensus and different perspectives on treatment of supracondylar fractures of the humerus in children. *Clin Orthop Surg* 4: 91-97.
  11. Ikram MA (1996) Ulnar nerve palsy: A complication following percutaneous fixation of supracondylar fractures of the humerus in children. *Injury* 27: 303-305.
  12. Nataraj AR, Sreenivas T, Naik J (2011) Comment on Memisoglu et al.: Does the technique of lateral cross-wiring (Dorgan's technique) reduce iatrogenic ulnar nerve injury? *Int Orthop* 35: 457-458.
  13. Oetgen ME, Mirick GE, Atwater L, et al. (2015) Complications and predictors of need for return to the operating room in the treatment of supracondylar humerus fractures in children. *Open Orthop J* 9: 139-142.
  14. Royce RO, Dutkowsky JP, Kasser JR, et al. (1991) Neurologic complications after K-wire fixation of supracondylar humerus fractures in children. *J Pediatr Orthop* 11: 191-194.
  15. Soldado F, Knorr J, Haddad S, et al. (2015) Ultrasound-guided percutaneous medial pinning of pediatric supracondylar humeral fractures to avoid ulnar nerve injury. *Arch Bone Jt Surg* 3: 169-172.
  16. Rasool MN (1998) Ulnar nerve injury after K-wire fixation of supracondylar humerus fractures in children. *J Pediatr Orthop* 18: 686-690.
  17. Padua L, Di Pasquale A, Liotta G, et al. (2013) Ultrasound as a useful tool in the diagnosis and management of traumatic nerve lesions. *Clin Neurophysiol* 124: 1237-1243.
  18. Omar N, Ditty B, Rozzelle C (2015) Medicolegal aspects of peripheral nerve injury. In: Tubbs S, Rizk E, Shoja M, *Nerves and Nerve Injuries Vol. 2*. Elsevier Science, US, 707-708.