



Case Report

DOI: 10.36959/453/578

A Failure Case of Double Button Plate Fixation for Treatment of Nonunion of Patella Fracture

Kai Sun, MD and Meng Fan, PhD*

Tianjin First Center Hospital, Fukang Road No. 24, Nankai District, China



Abstract

Objective: To investigate effect of double button plate fixation in the treatment of nonunion of patella fracture.

Methods: One patient with nonunion of patella fracture was treated with double button plate fixation.

Results: The operation and hospital stay time was 70 minutes and 5 days respectively. Range of motion (ROM) and knee society scores (KSS) was related to a greater increase. Patella fracture was unhealing after 21 weeks operation.

Conclusion: In this study, double button plate fixation technology for the treatment of nonunion of the patellar pole had the advantages of simple operation, rapid recovery, but it was unstable and leads to unhealing.

Keywords

Nonunion, Patella fracture, Double button Plate Fixation

Introduction

The rate of nonunion of patella fracture was 2.4%-4.8% [1]. For the patella nonunion with no symptom or slight symptom, because the knee joint function is acceptable, non-surgical treatment is often used clinically. However, in some patients with nonunion, there are steps on the articular surface of patella, often have obvious symptoms such as knee joint pain, limited flexion and extension activities, etc., which can often cause serious complications such as traumatic patellofemoral arthritis, joint degeneration, joint stiffness, etc [2,3]. The treatment of patellar nonunion is not unified. At present, there is still much controversy in the clinical treatment of comminuted fracture of inferior pole of patella fracture [4]. The commonly used surgical methods have open reduction and tension band wire fixation, cannulated screw steel wire internal fixation, partial patellar resection. In our previous study [5], an alternative is to utilize double button plate fixation methods. We have adopted double button plate fixation in the management of patella inferior fracture. Here, we report the results of the fixation techniques in the management of nonunion of patella fracture.

Cases Presentation

Patient demographics

We identified one case of patella fractures operated on at local department in September 2019. But the fracture was still not healing in March 2020 (Figure 1). The male with an age of 50 years. The patient received fixation by means

of double button plate. Fall injury on level ground was the mechanism of injury in last operation. This operation time was approximately 70 minutes. A follow-up period of 21 weeks was attained in the patient.

Surgical technique

Decision in regard to fixation method was determined intraoperatively by the surgeon based on its configuration. Nonunion of patella fracture was managed with double button plate, and those considered to be stability to prevent axial displacement. In our previous study [5], we have introduced detailedly the method. Briefly, we should remove original internal fixation, and exposed the nonunion fracture, then punctured into a diameter of 3.0 mm drill hole and inserted two wire button plates along the distal fracture fragments from the upper pole to the lower pole, proximal fracture fragments from the lower pole to the upper pole (Figure 2a, Figure 2b). During the operation, the active knee joint showed stable fracture, X-ray fluoroscopy showed good reduction of

***Corresponding author:** Meng Fan, PhD, Tianjin First Center Hospital, Fukang Road No. 24, Nankai District, Tianjin, 300192, China

Accepted: September 27, 2021

Published online: September 29, 2021

Citation: Sun K, Fan M (2021) A Failure Case of Double Button Plate Fixation for Treatment of Nonunion of Patella Fracture. J Orthop Surg Tech 4(2):387-390

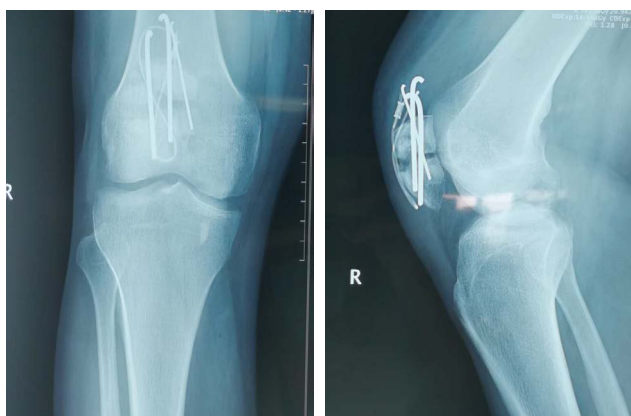

Figure 1: Preoperative radiograph of nonunion of patella fracture.

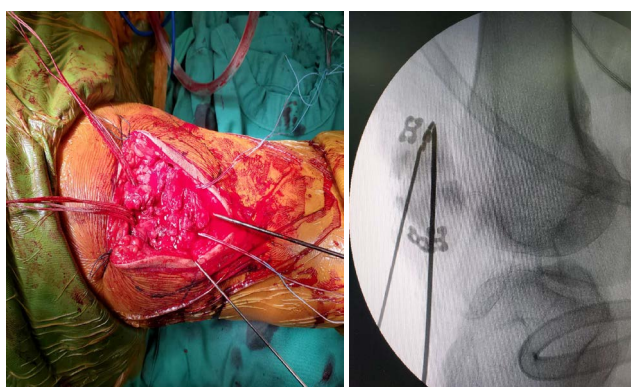


Figure 2a: Intraoperative radiograph of double button plate fixation.

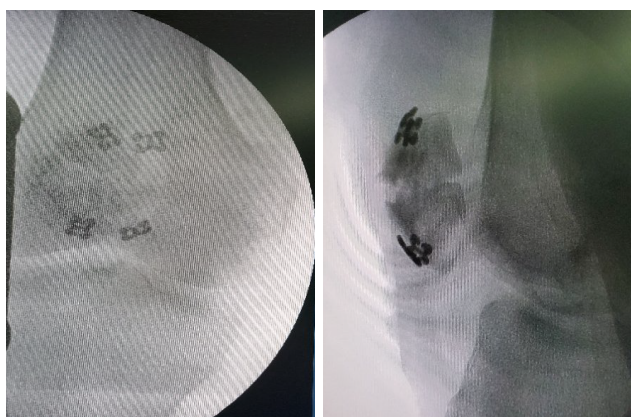

Figure 2b: Intraoperative radiograph of double button plate fixation.

fracture, and the position of titanium plate was acceptable. Limb was fixed with plaster at 0 degree of extension.

Postoperative care and follow-up

Postoperative radiographs were taken the day after surgery. Patient was given a plaster as protection postoperatively. In general, 0 to 90 degrees of flexion in-brace was allowed for first 4 weeks postoperatively. Patients were given their first follow-up appointment at 2 weeks postoperatively for wound inspection, then they were followed up every 2-4 weeks to monitor for functional return and clinical/radiological fracture union (Figure 3, Figure 4, Figure 5, Figure 6 and Figure 7).

Results

The case was loss of fracture fixation and delayed postoperative period again. Although the patient can kneel in the follow-up 6 weeks, no implant breakage, infection among, and was not noted to have double button plate dislodgement upon follow-up X-rays, the fracture was still unhealing and after 21 weeks operation, and demonstrated fracture displacement (Figure 8).

Radiological and Functional Outcomes

The case of incision healed well and the patella returned to normal by X-Ray after operation. At 3 weeks after operation, plaster were removed, patient had normal flexion and extension of the knee joint at 6 weeks, and 21 weeks after operation, the fracture still did not have reached the healing standard. Patient receiving metal fixation, demonstrated exist patella baja. During the follow-up period, radiological analysis showed reduction in patella height. Functional outcome was assessed by means of walking status and knee range of motion upon final follow-up (Table 1).

Discussion

The main causes of nonunion after patellar fracture are as follows: (1) premature movement after plaster fixation, premature weight-bearing, quadriceps traction leading to

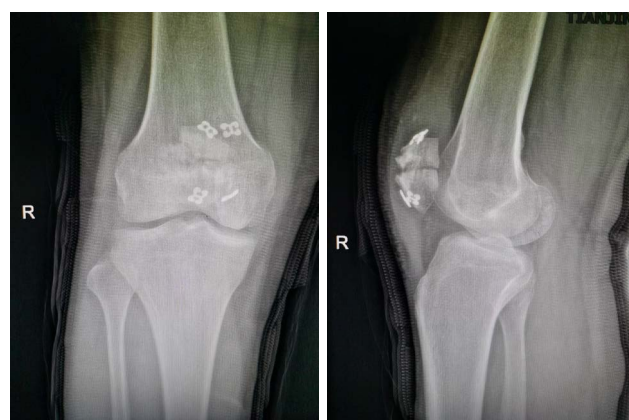


Figure 3: Postoperative radiograph of double button plate fixation (2 days).

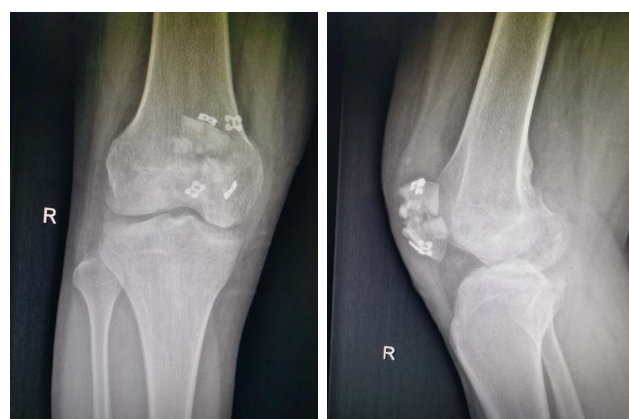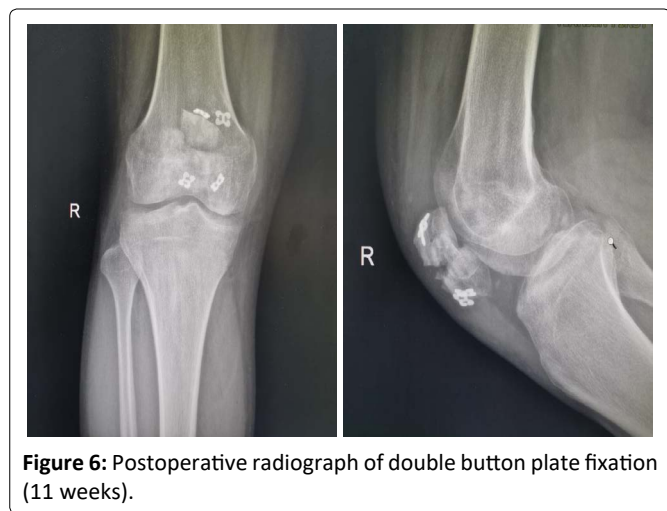
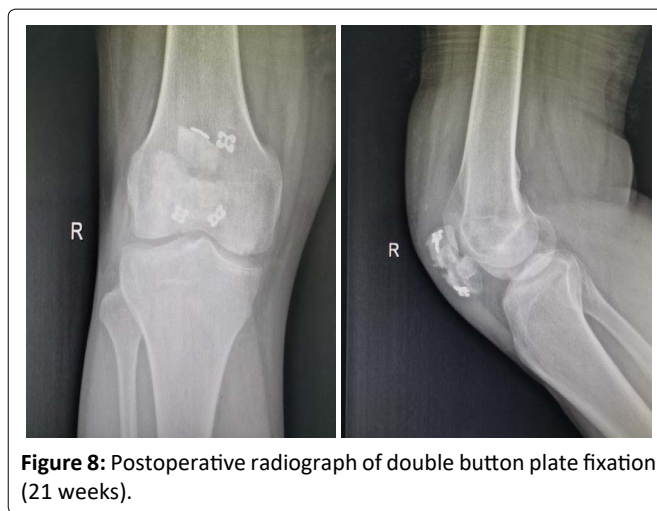
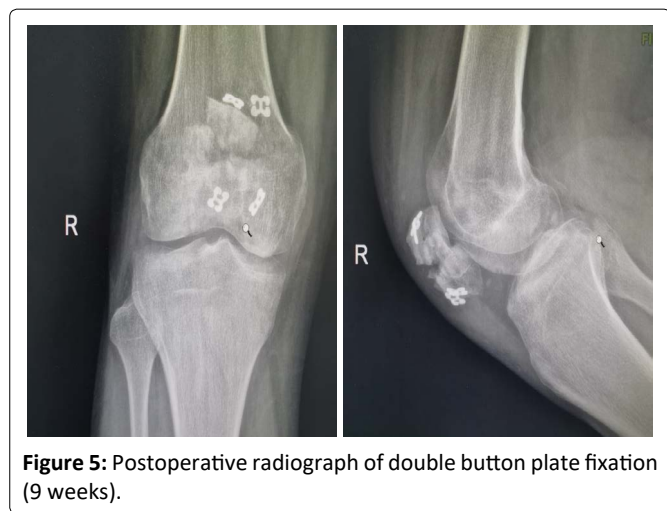


Figure 4: Postoperative radiograph of double button plate fixation (7 weeks).

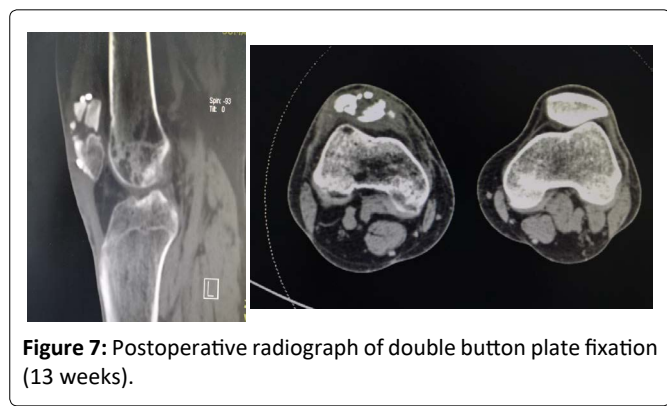
Table 1: Patient Demographics.

Demographics.	Sex	Age (year)	Injury	OT (minutes)	HST (days)	ROM (degree)	KSS function (scores)	FWB (weeks)
Patient	M	50	Fall	70	5	Preoperative 0-70 Postoperative 0-120	Preoperative 50 Postoperative 80	14
Nonunion	Yes							
Any infection	NO							
Revision	NO							

Abbreviations: M: Male; OT: Operation Time; HST: Hospital Stay Time; ROM: Range of Motion; KSS: Keen Society Score; FWB: Full Weight Bearing



fracture block separation, resulting in nonunion; (2) loose steel wire, wire cerclage or tension band fixation, resulting in fracture block separation under the traction of quadriceps femoris; (3) steel wire and wire cerclage fixation is too tight, but tendon or ligament around patella is cut during activity, and when the bone mass was not healed after operation, patient moved early until the internal fixation wire or wire was broken, and the internal fixation failed [6].



There is no clear standard for the indication of patellar nonunion [7]. It is generally believed that conservative treatment can be used for asymptomatic or mild patellar nonunion. For patients with obvious symptoms, surgical treatment is needed. The occurrence of patellar nonunion can not only damage the articular cartilage of femoral condyle, but also lead to traumatic arthritis of patellofemoral joint. Therefore, once the patellar fracture occurs nonunion, such as uneven articular surface or large gap, it should be treated as soon as possible. The treatment of patellar nonunion is not unified [8]. At present, the commonly used surgical methods are: Open reduction and tension band internal fixation, cannulated screw steel wire internal fixation, partial patellar resection and total patellar resection.

The principle of treatment of patellar nonunion is mainly to restore the continuity of knee extensor, rather than anatomical reduction of joints [9]. The implant provides reliable fixation and minimal implant protrusion, which is conducive to early functional exercise. For patients with patellar nonunion, a more classic treatment method is to insert two rivets into the broken end of the fracture, the

sutures were sewn out along the aponeurosis at both sides, then the two circuits were sewn and knotted with each other [5]. Compared with open reduction and tension band internal fixation, the use of double button plate fixation technology has the following advantages: (1) less trauma, convenient use of instruments and fixtures; (2) Double button plate fixation has little impact on the anatomical structure of the knee joint, but it can be unstable and leads to unhealing [5,10].

Conclusion

In this study, although double button plate fixation technology for the treatment of patellar nonunion has the advantages of simple operation, restoring patellar anatomical shape, reliable internal fixation, the fracture can be still unhealing after enough time operation, and demonstrated fracture displacement. At present, the treatment of patellar nonunion with double button plate has been carried out for a relatively short time, and the number of cases is relatively small. There are also shortcomings in this study, such as small sample size and insufficient follow-up time. Further expansion of sample size and long-term follow-up are needed to confirm this.

Competing Interests

The authors declare that they have no competing interests.

Ethical Approval and consent to participate

The study was approved by the institutional review board of Tianjin First Center Hospital and all authors and patients have read and approved the final manuscript. The experiment was examined and approved by Tianjin First Center Hospital Ethics Committee. Before the experiment, patients were asked to fill in the informed consent form and study participants was given consent to have their data published.

Consent for publication

All authors have read and approved the final manuscript.

Funding

The author(s) received no financial support for the research, authorship, and/or publication of this article.

Authors' contributions

Meng Fan designed the study protocol, participated in the data analysis, and drafted the manuscript. Kai Sun participated in the analysis and revision of the manuscript. All authors have read and approved the final manuscript.

Acknowledgements

The authors would like to thank Tianjin First Center Hospital for providing the database.

References

1. Buezo O, Cusco X, Seijas R, et al. (2015) Patellar fractures: An innovative surgical technique with transosseous suture to avoid implant removal. *Surg Innov* 22: 474-478.
2. Egol K, Howard D, Monroy A, et al. (2014) Patella fracture fixation with suture and wire: You reap what you sew. *Iowa Orthop J* 34: 63-67.
3. Carreira DA, Fox JA, Freedman KB, et al. (2005) Displaced nonunion patellar fracture following use of a patellar tendon autograft for ACL reconstruction: Case report. *J Knee Surg* 2: 131-134.
4. Seybold D, Hopf F, Kalicke T, et al. (2005) Avulsion fractures of the lower pole of the patella. *Unfallchirurg* 7: 591-596.
5. Meng Fan, Dong Wang, Kai Sun, et al. (2020) Study of double button plate fixation in treatment of inferior pole of patella fracture. *Injury* 51: 774-778.
6. Camarda L, Morello S, Balistreri F, et al. (2016) Non-metallic implant for patellar fracture fixation: A systematic review. *Injury* 47: 1613-1617.
7. Veselko M, Kastelec M (2005) Inferior patellar pole avulsion fractures: Osteosynthesis compared with pole resection. *Surgical technique. J Bone Joint Surg Am* 87:113-121.
8. Nathan ST, Fisher BE, Roberts CS, et al. (2011) The management of nonunion and delayed union of patella fractures: A systematic review of the literature. *Int Orthop* 35: 791-795.
9. Wright PB, Kosmopoulos V, Cote RE, et al. (2009) Fiber wire is superior in strength to stainless steel wire for tension band fixation of transverse patellar fractures. *Injury* 40: 1200-1203.
10. Curtis MJ (1990) Internal fixation for fractures of the patella. A comparison of two methods. *J Bone Joint Surg Br* 72: 280-282.

DOI: 10.36959/453/578