



Case Report

DOI: 10.36959/363/415

Posterior inferior Cerebellar Artery (PICA) Fusiform Aneurysm Ruptured Related with a Pure Arterial Malformation: Case Report and Technical Note (NBCA Embolization under Roadmap-Fluoroscopy)

Maria Del Rosario Sosa-Martinez, MD*, Guy G Broc-Haro, MD, Javier Valdes-Garcia, MD, Christopher Mader-Alba, MD and Daniel Juarez-Rebollar, MD



Department of Neurosurgery and Neurological Endovascular Therapy, "Lic. Adolfo López Mateos" Regional Hospital of the Security and Social Institute of the State Workers, Mexico

Abstract

The pure arterial malformation (PAM) lesion has been recently described as a vascular pathology characterized by the sole presence of coiled, sometimes ecstatic, arterial loops.

2% of the fusiform aneurysms are located in the vertebral-posterior inferior cerebellar arteries.

A 60 years old female with subarachnoid hemorrhage was diagnosed with a fusiform aneurysm in the right PICA related with a PAM in the digital subtraction angiography (DSA). With a negative super-selective Wada test; the patient was treated with embolization of the two lesions and the PICA for being in the same arterial territory with adhesive embolic liquid under roadmap fluoroscopy technique.

Conclusion: These two vascular lesions located in the same artery are very rare and more in the PICA territory. Is important to make the best decision to treat them because the potential complications; that's why the procedure were supported with super-selective Wada test and neuromonitoring of the PICA territory.

The injection of the mixture of NBCA and Lipiodol® under roadmap fluoroscopy is very safe.

Keywords

Fusiform aneurysm, Pure arterial malformation, N-butyl cyanoacrylate, Roadmap fluoroscopy

Background

The pure arterial malformation (PAM) lesion has been recently described as a vascular pathology characterized by the sole presence of coiled, sometimes ecstatic arterial loops [1]. These lesions are commonly mistaken for aneurysms or arteriovenous malformations [2].

Dolichoectatic arteries and fusiform aneurysms are related to arteriopathies and connective tissue diseases, and just 2% of the intracranial aneurysms are located in the vertebral-posterior inferior cerebellar arteries (PICAs) [3].

N-butyl cyanoacrylate (NBCA) is commonly used liquid embolic agent in the endovascular treatment of cerebrovascular and peripheral vascular pathologies. Although NBCA is most commonly known as an endovascular treatment option for cerebral arteriovenous malformation, neurointerventionalist have begun to utilize cyanoacrylate glues for several vascular brain pathologies [4,5].

***Corresponding author:** María del Rosario Sosa Martínez MD, Department of Neurosurgery and Neurological Endovascular Therapy, "Lic. Adolfo López Mateos" Regional Hospital of the Security and Social Institute of the State Workers, Universidad #1321 Colonia La Florida, Alcaldía Álvaro Obregón. Ciudad de, Ext 89241, México, Tel: + (55)5322 2300

Accepted: June 28, 2021

Published online: June 30, 2021

Citation: Sosa-Martinez MDR, Broc-Haro GG, Valdes-Garcia J, et al. (2021) Posterior inferior Cerebellar Artery (PICA) Fusiform Aneurysm Ruptured Related with a Pure Arterial Malformation: Case Report and Technical Note (NBCA Embolization under Roadmap-Fluoroscopy). J Neurosurg Res Rev 4(1):50-54

Case Report

A 60 years old female, with clinical history of hypertension on enalapril twice daily and no allergies reported. She started 5 days previous admission to the hospital with intensive oppressive headache 10/10 of EVA scale, without neurological focalization and no meningeal signs in the physical examination. The head non-contrast CT scan showed subarachnoid hemorrhage grade IV in the Fisher scale. The DSA demonstrated a fusiform aneurysm and a PAM in the second and third segment of the right PICA respectively (Figure 1). Analyzing the clinical status and the invasive and non-invasive images of the studies of the patient, we decided to embolize the both lesions as well to occlude the PICA for being in the same arterial territory.

The procedure was performed as follows: with the patient awake, analgesia and local anesthesia, neurophysiologic monitoring, super-selective Wada test with 1cc propofol injected in the right PICA obtaining as result, no neurophysiological deficit and clinically did not developed a Wallenberg syndrome.

We proceeded to embolization both lesions and the right PICA with NBCA and Lipiodol. The patient returned to the ICU, and she had a satisfactory clinical evolution and no added neurological deficit, so she was discharged 3 days after the treatment.

Embolization Technique

We approached the right femoral artery with a 6F sheath. For the right vertebral hypoplastic artery was used a 5F Chaperon® for the coaxial system with a 1.5 Headway Duo® microcatheter and a Xpedion™ 10 microwire for the super-selective catheterization of the right PICA under roadmap fluoroscopy technique and done a super-selective angiogram (Figure 2) A provocative Wada test was performed with 1 cc of propofol injected in the right PICA supported with neuromonitoring and physical exploration of the patient. The result of the test was negative for a neurological deficit. A load dose of dexamethasone was given intravenously, the microcatheter in optimal position was flushed with 10 cc of 5% glucose solution, the embolization was done with a dilution 1:8 of NBCA and Lipiodol® under roadmap fluoroscopy technique in a Philips Allura (Figure 3).

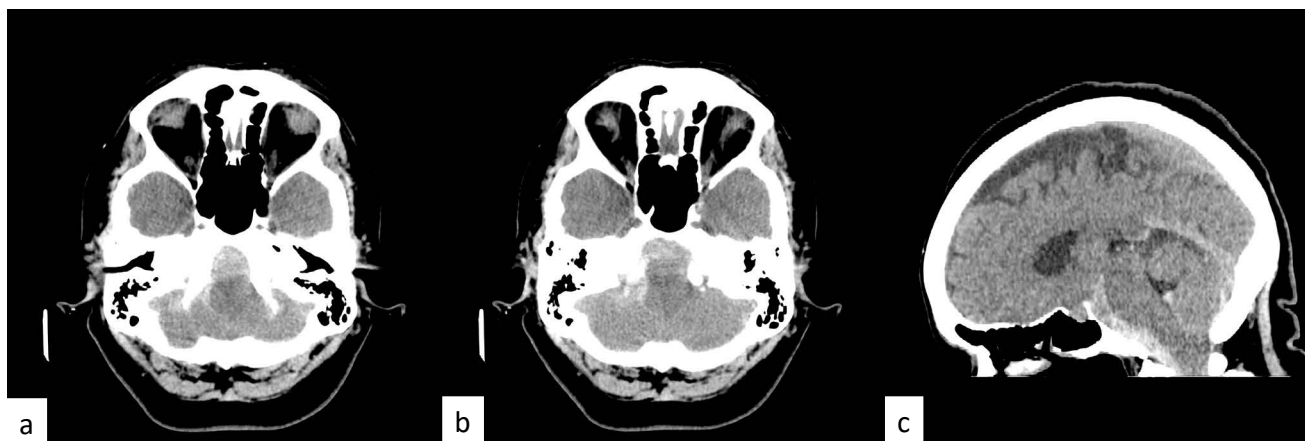


Figure 1: a), b) and c) CT scan demonstrated subarachnoid hemorrhage predominantly in the prebulbar and prepontine cisterns and in the IV ventricle. A grade IV in the Fisher scale.

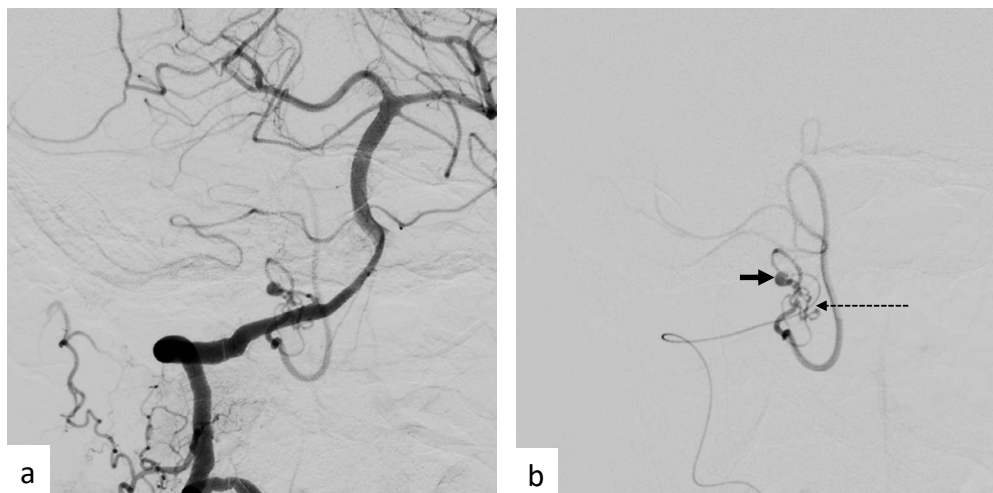


Figure 2: DSA of the right vertebral artery a) AP Towne projection and b) Super-selective injection of the right PICA: shows the proximal fusiform aneurysm (second segment) indicated with the black arrow and distal the PAM indicated with the discontinued black arrow (third segment).

In the ending rounds of the DSA showed total exclusion of the aneurysm, AM and the right PICA occlusion; the parenchymogram demonstrated no vascular defects (Figure 4).

The femoral artery was closed with Angioseal® 6F and the control non contrast CT scan did not demonstrate hemorrhage or ischemic stroke (Figure 5).

Discussion

In pure arterial malformations the overlapping, dilated and tortuous trajectory are coil-like appearance in all population ages and may have genetic, infectious, inflammatory, immunological or degenerative predisposing factors that may cause or contribute to the formation and/or progression of

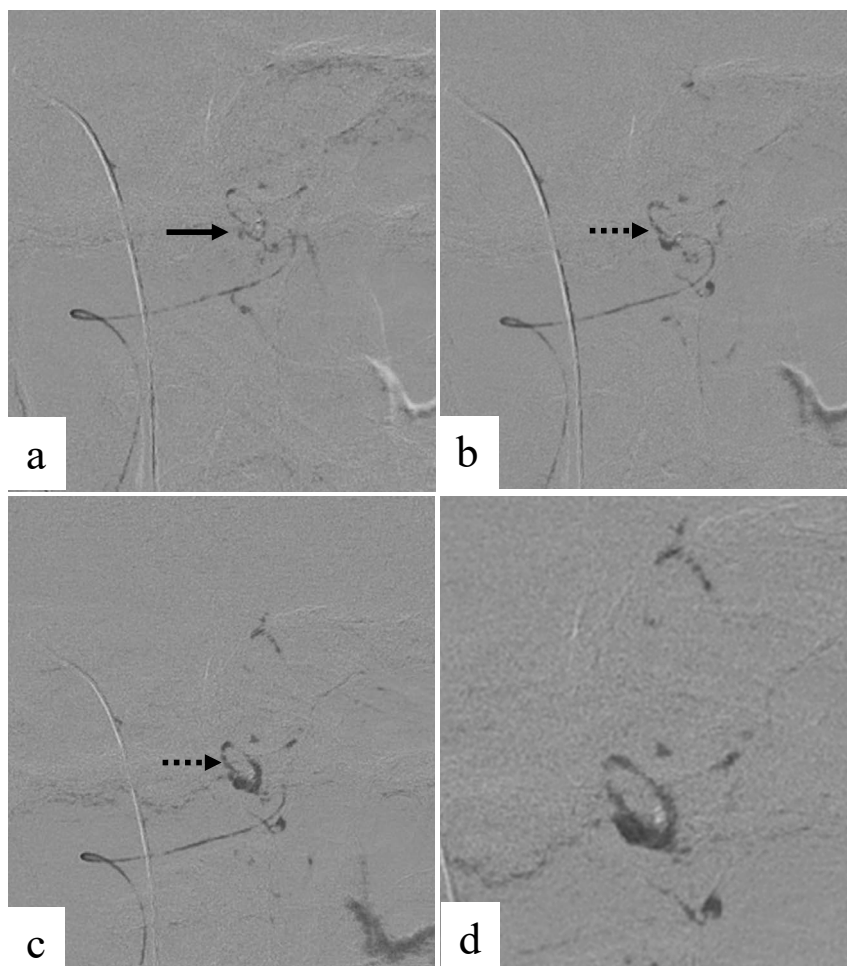


Figure 3: The NBCA diluted with Lipiodol® was injected under roadmap fluoroscopy technique. a) We see the microcatheter tip and the beginning of the embolization of the adhesive liquid mixture (black arrow). b) and c) We demonstrate the radiopacity, advanced and penetration of the NBCA + Lipiodol® with this technique (black discontinued arrow). d) The roadmap fluoroscopy last round with the detached of the microcatheter.

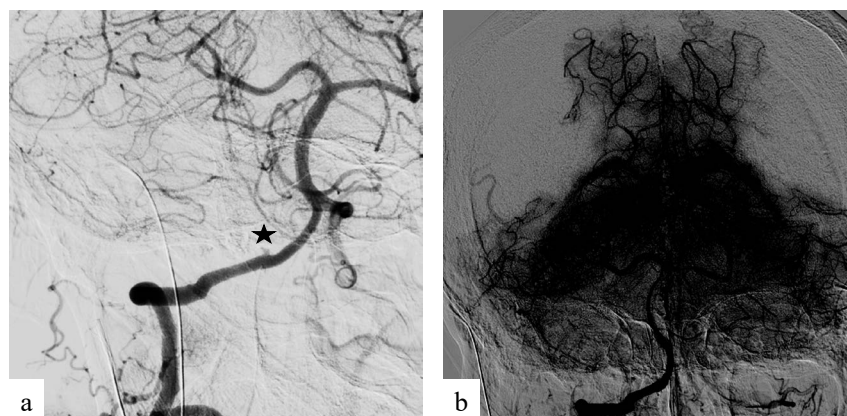


Figure 4: Postoperative control DSA. a) The aneurysm, pure arterial malformation and the PICA are excluded (black star) of the arterial circulation. b) No vascular zone defect in the caudal portion of the cerebellum in the parenchymogram.

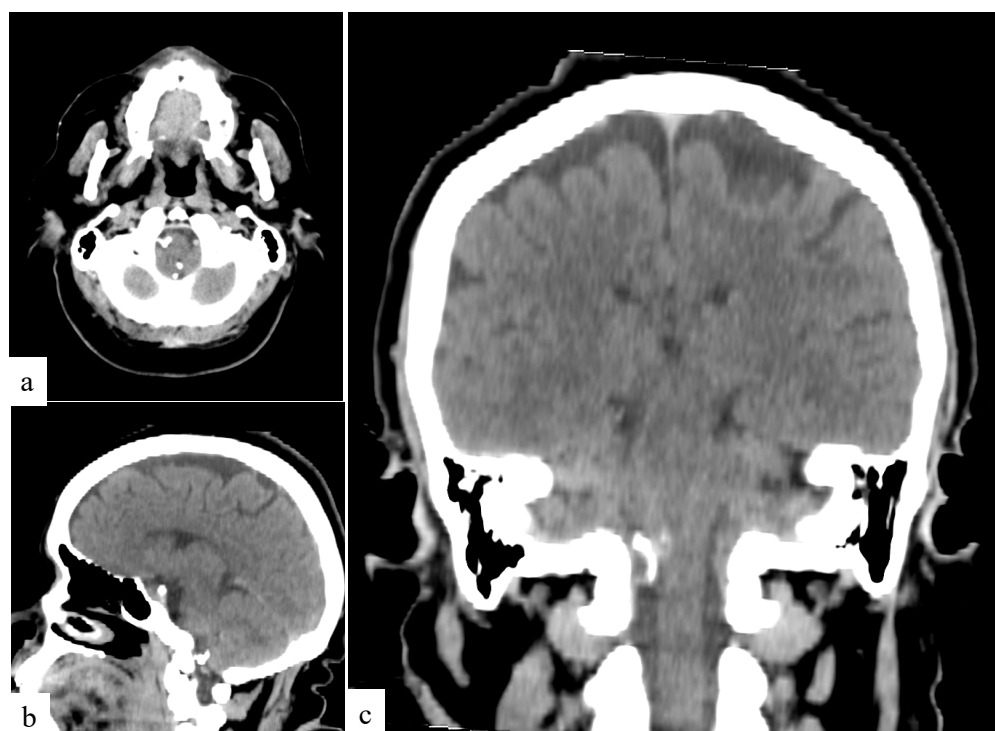


Figure 5: Non contrast head CT scan a) Axial, b) Sagittal c) Coronal projection revealed the radiopacity and no artifact generated by the liquid embolic material in the PICA territory. In all imagens there is no evidence of hemorrhage or ischemic stroke.

the arteriopathy. The appropriate characterization of the vasculopathy architecture is paramount important for choose the best treatment and prognosis varies depending on the type of the vascular anomalies [6].

Aneurysms arising from the PICA distal to the origin from the vertebral artery are rare, represents 0.5 - 3% of all intracranial aneurysms. The fusiform geometry is considered when they had no discernible neck [7]. And PICA aneurysms are most commonly discovered when patients presents subarachnoid hemorrhage (SAH), although patients can occasionally present symptoms related to the medulla and cranial nerves IX - XI. These lesions can be treated by surgery and has several advantages, as immediate decompression by removal the blood clot and identification of the bleeding sources in cases with multiple lesions and decrease the risk of re-ruptured [8,9]. Approximately 20 to 66% of the lower cranial nerve's deficits are associated with open surgery. However, several studies have been published stating the usefulness of endovascular management that avoids the manipulation of the posterior fossa structures [9].

To evaluated a possible infarction of the PICA territory, we used super-selective provocative test with propofol. This anesthetic has a safety margin, low incidence of side effects, and effectiveness in inducing controlled transitory losses of neurologic function in the perfused areas [10,11].

The embolization was done with previous IV load dose of dexamethasone and the microcatheter flushed with 10 cc of 5% glucose. With N-butyl cyanoacrylate (NBCA) and Lipiodol® with a dilution 1:8, under roadmap fluoroscopy technique; the injection of the glue mixture thru the right PICA was for 65 seconds (Figure 4). We showed the good visualization, advance and penetration of the embolic liquid mixture during

the injection and excellent control of the reflux at the tip of the microcatheter; thesis important to accomplish the goal of the procedure as well as to choose the right moment for the withdrawal of the microcatheter.

The iodine component of the Lipiodol® determinate it's the radiopacity so during the injection of this embolic material under roadmap fluoroscopy technique and makes unnecessary the addition of tantalum or tungsten for the proper control and visualization during the injection as when using fluoroscopy only.

Lipiodol® has 2 functions: delays the polymerization of the NBCA by shielding it from surrounding ionic substances and the radiopacity during the injection under roadmap fluoroscopy.

The glue composition depends on the hemodynamic characteristics of the targeted lesion to calculated the viscosity of the embolic [12] and the radiopacity adding tantalum or tungsten powder to increase the visibility of the mixture in the conventional fluoroscopy technique [13-15].

Conclusion

There is a low incidence of a fusiform and a pure arterial malformation in the same intracranial arterial territory. The endovascular technique is a secure procedure, because during the treatment you can do neurological provocative test and decide the most suitable management.

The utilization of the roadmap fluoroscopy technique during the injection of the mixture of NBCA and Lipiodol®, gives to the operator the visibility of the radiopacity, advance and penetration of the glue as well the reflux at the microcatheter tip without adding tantalum and tungsten.

Acknowledgement

Jorge L. Balderrama Bañares MD. Chief of the Neurological Endovascular Therapy Service of the Neurology and Neurosurgery National Institute. Mexico City.

For his advices for management of complexes clinical cases.

Statement of Ethics

The authors have no ethical conflicts.

Disclosure Statement

The authors have no ethical conflicts.

References

1. Thomas J Sorenson, Waleed Brinjikji, Kelly D Flemming, et al. (2018) Pure arterial malformation of the posterior inferior cerebellar artery with interspersed adipose tissue: Case report. *J Neurosurg Pediatr* 22: 261-264.
2. Brinjikji W, Cloft HJ, Flemming KD, et al. (2018) Pure arterial malformations. *J Neurosurgery* 129: 91-99.
3. Steiger JH, Etmainan N, Hanggi D (2015) Microsurgical brain aneurysms. Springer.
4. Cuoco JA, Williams EL, Kellin BJ, et al. (2020) N-butyl cyanoacrylate embolization of a traumatic pseudoaneurysm and arteriovenous fistula of the middle meningeal artery. *Radiol Case Rep* 15: 321-325.
5. Kim Dh, Lee JY, Jeon HJ, et al. (2015) Intraoperative endovascular embolization of middle meningeal artery and pseudoaneurysm by using N butyl 2 cyanoacrylate for hemostasis during operation of acute epidural hemorrhage. *Korean J Neurotrauma* 11: 167-169.
6. McLaughlin N, Raychev R, Duckwiler G, (2013) Pure arterial malformation of the posterior cerebral artery: Importance of its recognition. *J Neurosurg* 119: 655 - 660.
7. Nussbaum ES, Mendez A, Paul Camarata, et al. (2003) Surgical management of fusiform aneurysms of the peripheral posteroinferior cerebellar artery. *Neurosurgery* 53: 831 - 835.
8. Lewis SB, Chang DJ, Peace DA, et al. (2002) Distal posterior inferior cerebellar artery aneurysms: Clinical features and management. *J Neurosurg* 97: 756-766.
9. Xu F, Hong Y, Zheng Y et al. (2017) Endovascular treatment of posterior inferior cerebellar artery aneurysms: A 7-year single center experience. *J Neurointerv Surg* 9: 45-51.
10. Feliciano CE, De León-Berra R, Hernández Gaitán MS et al. (2010) Provocative test with propofol: Experience in patients with cerebral arteriovenous malformations who underwent neuroendovascular procedures. *AJNR Am J Neuroradiol* 31: 470-475.
11. Curot J, Denuelle M, Busigny T, et al. (2014) Bilateral Wada test: Amobarbital or propofol? *Seizure* 23: 122-128.
12. Gonzalez LF, Albuquerque FC, McDougall C (2015) Neurointerventional techniques. *Tricks of the trade*.
13. n-BCA Trial Investigators (2002) N-Butyl Cyanoacrylate embolization of cerebral arteriovenous malformations: Results of a prospective, randomized, multi-center trial. *AJNR Am J Neuroradiol* 23: 748-755.
14. Tamatani S, Koike T, Ito Y, et al. (2000) Embolization of arteriovenous malformation with diluted mixture of NBCA. *Interv Neuroradiol* 6: 187-190.
15. Takeuchi Y, Morishita H, Sato Y, et al. (2014) Guidelines for the use of NBCA in vascular embolization devised by the Committee of Practice Guidelines of the Japanese Society of Interventional Radiology. *J Radiol* 32: 500-517.

DOI: 10.36959/363/415