



## Extreme Laparoscopic Transillumination

Samsiya Ona and James A Greenberg\*

Department of Obstetrics & Gynecology, Brigham & Women's Hospital, Harvard Medical School, USA

### Keywords

Hysterectomy, Laparoscopy, Transillumination

### Description of Image

A 46-year-old female with a body mass index (BMI) of 19 was undergoing a laparoscopic hysterectomy for uterine leiomyomata. After insufflating the abdomen, placing the trocars and turning down the room lights, this dramatic image of the transilluminated abdomen with highlighting of the rectus musculature was encountered. The procedure was uneventful (Figure 1).

### Disclosure Statement

The authors declare that they have no conflicts of interest and nothing to disclose.

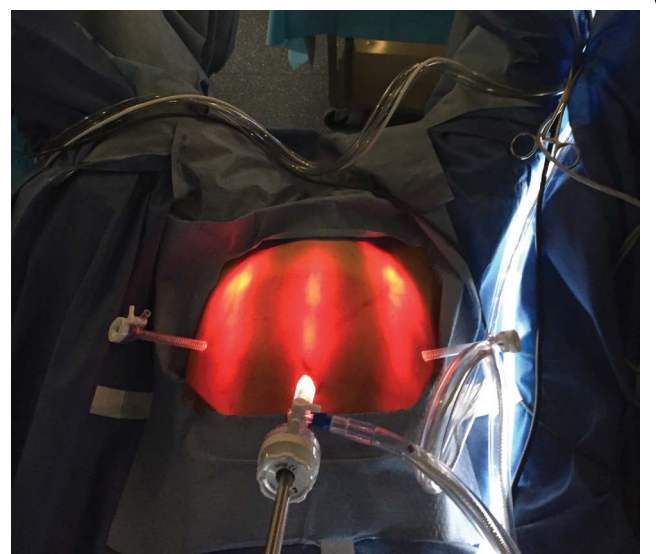


Figure 1: Laparoscopic hysterectomy Transillumination.

**\*Corresponding author:** James A Greenberg, MD, Department of Obstetrics & Gynecology, Brigham & Women's Hospital, Harvard Medical School, 1153 Centre Street, Suite 3C, Boston, MA 02130, Massachusetts, USA, Tel: 781-910-1968, E-mail: [jagreenberg@bwh.harvard.edu](mailto:jagreenberg@bwh.harvard.edu)

**Received:** September 14, 2017; **Accepted:** June 27, 2018;  
**Published online:** June 30, 2018

**Citation:** Ona S, Greenberg JA (2018) Extreme Laparoscopic Transillumination. Reports Gynecol Surg 1(1):11