



Clinical Image

DOI: 10.36959/592/393

Transcranial Doppler Ultrasonography in the Diagnosis of Brain Aneurysm

Issac Cheong*

Intensive Care Unit, Department of Critical Care Medicine, Sanatorio De los Arcos, Argentina

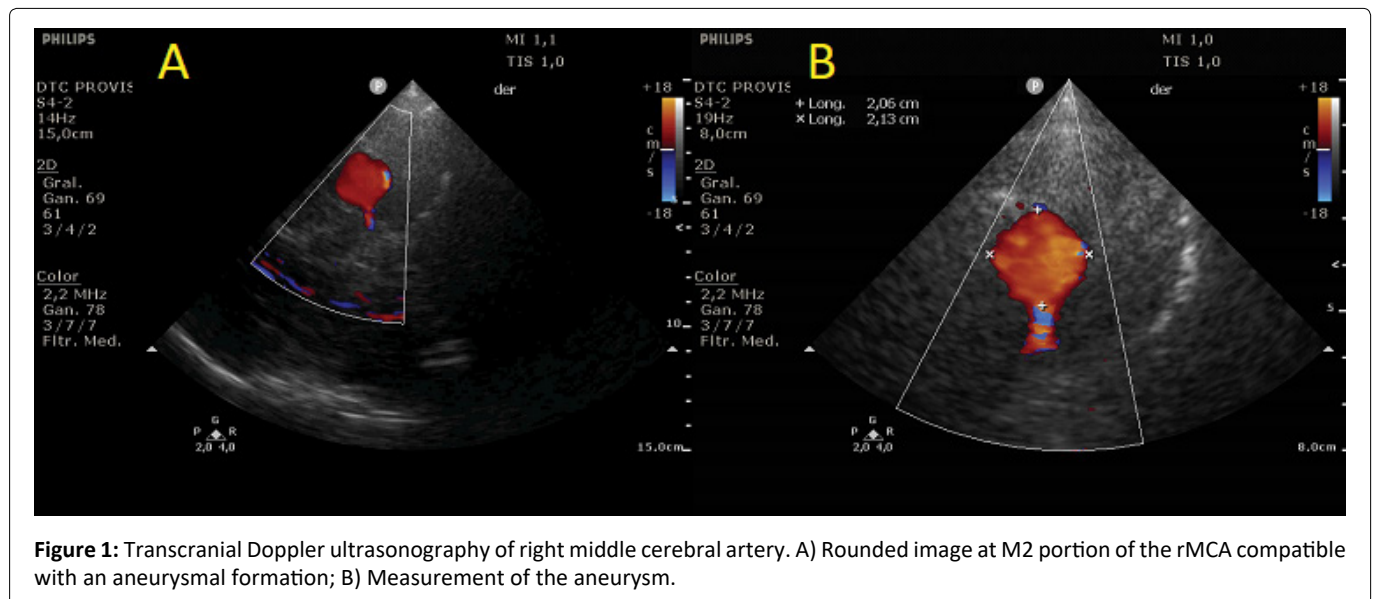


Figure 1: Transcranial Doppler ultrasonography of right middle cerebral artery. A) Rounded image at M2 portion of the rMCA compatible with an aneurysmal formation; B) Measurement of the aneurysm.

Clinical Image

A 50-year-old male with no relevant clinical history presented sudden headache accompanied by nausea, which evolved with facial paresis and drowsiness with a computed tomography (CT) showing bilateral subarachnoid bleeding, being admitted to the intensive care unit. We performed a transcranial doppler ultrasonography (TCD) that showed the presence of a rounded image at M2 portion of the right middle cerebral artery (rMCA) that measured 20 mm × 21 mm with a positive color Doppler signal [Figure 1](#). CT angiography with 3D reconstruction showed an aneurysmal formation of 20 mm in the projection of the rMCA and another small one at the level

of the left middle cerebral artery [Figure 2](#). An angiography of intracerebral vessels confirmed a giant aneurysm of 22 mm × 25 mm at the rMCA, requiring stent placement and embolization of the aneurysm with coils. During the hospital stay, he presented vasospasm of the rMCA with a good response to treatment, evolving clinically stable, with subsequent discharge. This case demonstrates that TCD can be useful for the diagnosis of cerebral aneurysms.

Conflicts of Interest

The author declares that he has no conflict of interest.

***Corresponding author:** Issac Cheong, Intensive Care Unit, Department of Critical Care Medicine, Sanatorio De los Arcos, Juan B. Justo 909, CABA, Buenos Aires, Argentina

Accepted: June 06, 2022

Published online: June 08, 2022

Citation: Cheong I (2022) Transcranial Doppler Ultrasonography in the Diagnosis of Brain Aneurysm. *Sch J Emerg Med Crit Care* 6(1):123-124

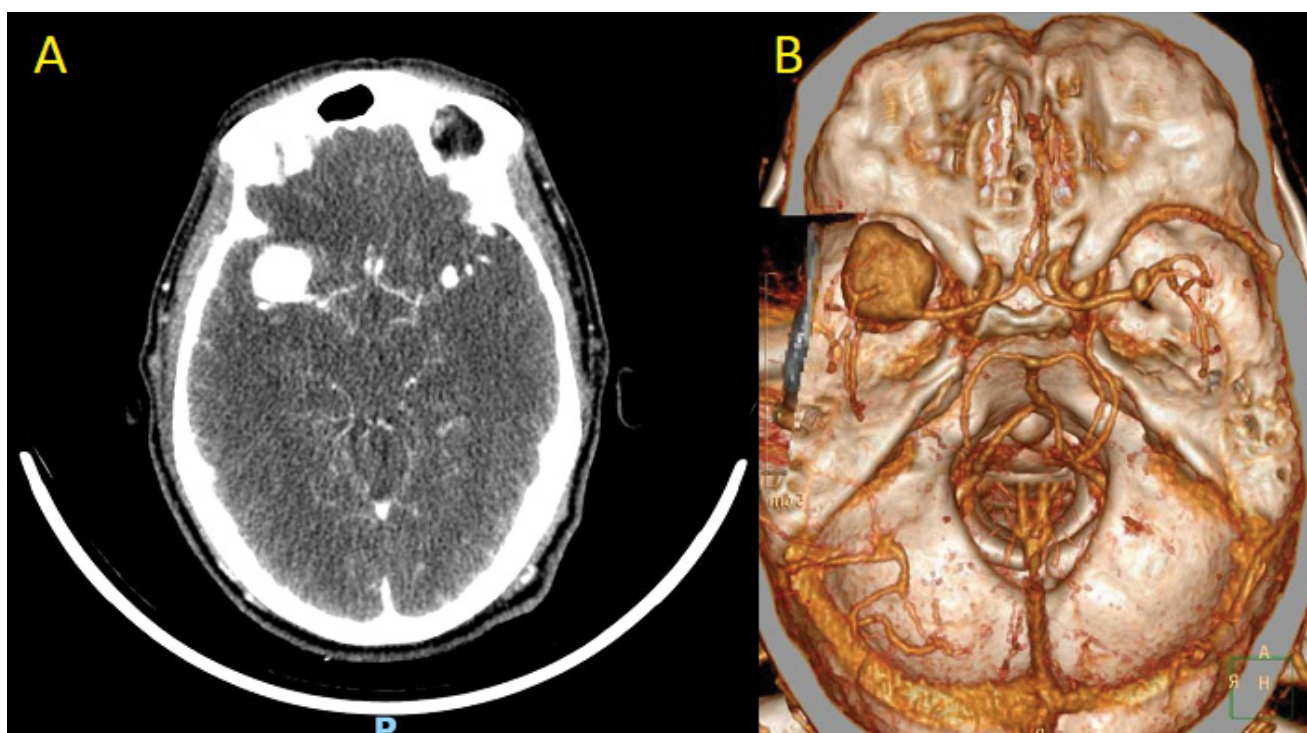


Figure 2: A) CT angiography of brain; B) CT angiography with 3D reconstruction of brain.

DOI: 10.36959/592/393

Copyright: © 2022 Cheong I. This is an open-access article distributed under the terms of the Creative Commons Attribution License, which permits unrestricted use, distribution, and reproduction in any medium, provided the original author and source are credited.

