



Research Article

DOI: 10.36959/582/445

Benefit of Posterior Pericardiotomy in Heart Valve Surgery

Yasser Mubarak*

Department of Cardiothoracic Surgery, Minia University, Egypt



Abstract

Objective: Posterior pericardiotomy (PP) is helpful to prevent arrhythmia; especially atrial fibrillation (AF), and cardiac tamponade postoperative cardiac valve surgery. The incidence of postoperative AF is increased due to postoperative pericardial effusion (PE). This study aimed to investigate the early outcome of PP after heart valve surgery.

Patient and method: In this prospective study, 120 patients underwent elective valve heart surgery at our center from January 2020 until April 2022. Patients were followed up for AF and pericardial effusion, and reopening due to tamponade.

Results: The mean age of patients was 35.26-years, 70.2% were female and 29.8% were male. Surgery was elective and all were valve surgery. The incidence of postoperative AF was 2%, and pericardial effusion was seen in 1% patients. Tamponade was not seen in any case. Left PE needed intervention tube drainage 2%.

Conclusion: Posterior pericardiotomy is a simple and safe procedure during valve heart surgery, and it is effective in reducing the incidence of atrial fibrillation, pericardial effusion, and tamponade.

Keywords

Posterior Pericardiotomy, Atrial Fibrillation, Pericardial Effusion, Tamponade

Introduction

Open heart surgery especially valve replacement or repair is very common [1]. Atrial fibrillation (AF) is the most common complication after cardiac surgery. Pericardial effusion (PE) is seen in more than 65% of patients. Even small amounts of Postoperative PE may trigger atrial arrhythmias due to local inflammation and oxidative damage. Posterior left pericardiotomy allows prolonged drainage of pericardial fluid into pleural space. It may be accumulated to cause hemodynamic impairment (tamponade) may be severe enough to cause tamponade [2].

Postoperative posterior PE is very difficult to be drained. Long standing hospital stay is required to follow up pericardial effusion with transthoracic echo (TTE). Medication is added to avoid increasing PE, and it may affect coagulation profile of patient. However, in case of tamponade, emergency sternotomy is needed [3].

Posterior pericardiotomy (PP) is a safe procedure that can be performed during surgery preventing PE and its complications [4].

Patients and Methods

Posterior pericardial window or posterior pericardiotomy (PP) was performed in 120 patients underwent elective

heart valve surgery (single or double or triple valve repair or replacement) from January 2020 until April 2022. We evaluated the early outcome of PP. The mean age of patients was 35.26-years, 70.2% were female and 29.8% were male. The incidence of postoperative AF, pericardial effusion, tamponade, and left pleural effusion needed chest tube drainage were followed up. Exclusion criteria included the presence of preoperative AF, heart failure, renal impairment, coagulation disorders and chronic liver disease.

Posterior pericardiotomy, 4 cm window is made posterior and parallel to the left phrenic nerve from the left inferior pulmonary vein to the diaphragm, creating an oval opening into the left pleural cavity like a siphon mechanism. It may be performed on cardiopulmonary bypass before aortic cross clamped or at the end of valve surgery according to hazards of elevated heart especially in case of mitral valve replacement. Another drain was inserted in left 5th intercostal space mid-

***Corresponding author:** Yasser Mubarak, Department of Cardiothoracic Surgery, Minia University, Egypt

Accepted: September 28, 2022

Published online: September 30, 2022

Citation: Mubarak Y (2022) Benefit of Posterior Pericardiotomy in Heart Valve Surgery. J Cardiothorac Surg Ther 6(1):142-143

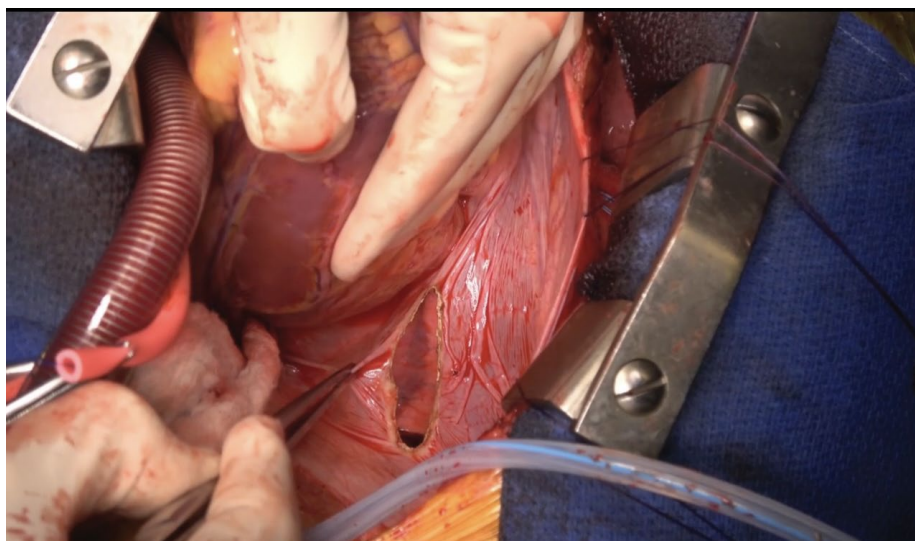


Figure 1: Posterior pericardial window.

axillary line to drain left pleura space (Figure 1).

Results

Out of total 120 patients, the mean age of patients was 35.26-years, 70.2% were female and 29.8% were male. Surgery was elective and all were valve surgery. The incidence of postoperative AF was 2%, and pericardial effusion was seen in 1% patients. Tamponade was not seen in any case. Left PE needed intervention tube drainage 2%. The average chest drain discharge was 235.35 ml; the mean ICU stay and total hospital time were 1.5 and 6.12 respectively. There were no prolonged mechanical ventilation time, no reopening for tamponade, and no readmission for pericardial effusion follow up.

Discussion

Postoperative pericardial effusion and arrhythmia (especially AF) are the most important, and serious postoperative complications [2]. PE is a common complication post cardiac surgery especial heart valve surgery, and its incidence is 43-74% of cases [3]. All pericardial effusion after operation is usually drained in left pleural space and absorbed. So, the risk factor of AF is decreased in addition to decrease the incidence of AF.

Post-cardiac valve surgery, AF has an impact on ICU, hospital stay, and readmission [4]. So, we perform safe and simple procedure, which is decreasing the cost and improving care of patients.

The incidence of AF in PP study group was 20% and in the control group was 26%, which is not a significant decreased; however, a significant reduction in pericardial effusion was recorded [5]. We managed all other causes and risk factors of arrhythmias to observe the outcome affected by only one variable.

Posterior pericardiotomy was significantly reduced the incidence of pericardial tamponade [6]. We did not perform sternotomy for emergency tamponade in our cases.

Conclusion

Posterior pericardiotomy is a simple and safe procedure avoiding atrial fibrillation, and tamponade.

Limitations

In our study, posterior pericardiotomy was used in all patients and therefore there was no control group, moreover no all open heart surgery cases but only valve surgery.

Conflict of Interest

There is no conflict of interests.

References

1. Filardo G, Hamilton C, Hebel Jr RF, et al. (2009) New-onset postoperative atrial fibrillation after isolated coronary artery bypass graft surgery and long-term survival. *Circ Cardiovasc Qual Outcomes* 2: 164-169.
2. Nisanoglu V, Erdil N, Aldemir M, et al. (2007) Atrial fibrillation after coronary artery bypass grafting in elderly patients: incidence and risk factor analysis. *Thorac Cardiovasc Surg* 55: 32-38.
3. Farsak B, Gunaydin Günaydin S, Tokmakoglu Tokmakoglu H, et al. (2002) Posterior pericardiotomy reduces the incidence of supra-ventricular arrhythmias and pericardial effusion after coronary artery bypass grafting. *Eur J Cardiothorac Surg* 22: 278-281.
4. Hu XL, Chen Y, Zhou ZD, et al. (2016) Posterior pericardiotomy for the prevention of atrial fibrillation after coronary artery bypass grafting: A meta-analysis of randomized controlled trials. *Int J Cardiol* 215: 252-256.
5. Alawami M, Chatfield A, Ghashi R, et al. (2018) Atrial fibrillation after cardiac surgery: Prevention and management: The Australasian experience. *J Saudi Heart Assoc* 30: 40-46.
6. Gupta R, Dhaduk K, Harburger J, et al. (2019) Can posterior pericardiotomy reduce the incidence of postoperative atrial fibrillation after coronary artery bypass grafting? *Journal of Cardiac Failure* 25: S84.